Tohoku J. Exp. Med., 2014, **232**, 301-304

Severe Acute Otitis Media Caused by Mucoid *Streptococcus Pyogenes* in a Previously Healthy Adult

Risako Kakuta,[1,2] Hisakazu Yano,[2] Hiroshi Hidaka,[1] Hiromitsu Miyazaki,[1] Mihoko Irimada,[3] Kiyoshi Oda,[3] Kazuaki Arai,[4] Daiki Ozawa,[1,2] Takashi Takahashi,[4,5] Mitsuo Kaku[2] and Yukio Katori[1]

[1]Department of Otolaryngology, Head and Neck Surgery, Tohoku University Graduate School of Medicine, Sendai, Miyagi, Japan
[2]Department of Infection Control and Laboratory Diagnostics, Tohoku University Graduate School of Medicine, Sendai, Miyagi, Japan
[3]Department of Otolaryngology, Tohoku Rosai Hospital, Sendai, Miyagi, Japan
[4]Laboratory of Infectious Diseases, Kitasato Institute for Life Sciences, Kitasato University, Tokyo, Japan
[5]Laboratory of Infectious Diseases, Graduate School of Infection Control Sciences, Kitasato University, Tokyo, Japan

Streptococcus (*S.*) *pyogenes* is well recognized as the most common pathogen causing pharyngotonsillitis in school-age children. In Japan, mucoid *Streptococcus pneumoniae* is well known as a causative agent of severe acute otitis media (AOM); however, mucoid *S. pyogenes* has rarely been reported. To the best of our knowledge, this is the first report of an AOM patient caused by mucoid *S. pyogenes* in Japan. A 36-year-old previously healthy female was referred to our hospital with suspicion of cerebrospinal otorrhea due to increasing otalgia accompanied by headache following myringotomy. Bacterial cultures of middle ear secretions were performed, and mucoid-form colonies surrounded by zones of complete *β*-hemolysis were produced on sheep's blood agar. Antigen-agglutination test results were positive for *S. pyogenes*, and thus the patient received treatment with panipenem-betamipron 2.0 g/day for 10 days, which resolved nearly all symptoms. The bacteriological features of this strain were then investigated. The M-protein genotype encoded by the *emm* gene, the major virulence factor of *S. pyogenes*, was determined to be *emm*75. Generally, *S. pyogenes* forms colonies having non-mucoid matt appearances based on *β*-hemolysis of sheep's blood agar. The mucoid phenotype results from abundant production of hyaluronic acid capsular polysaccharide, a key virulence determinant. *emm*75 is common in noninvasive, but less common in invasive disease. In conclusion, mucoid *S. pyogenes* can cause severe infection even in previously healthy persons. Emergence of mucoid *S. pyogenes* and drug resistance trends should be monitored in the future.

Keywords: *emm*; macrolide resistance; mucoid; otitis media; *Streptococcus pyogenes*
Tohoku J. Exp. Med., 2014 April, **232** (4), 301-304.

Introduction

Streptococcus (*S.*) *pyogenes* is a Gram-positive coccus that is by far the most common cause of acute bacterial pharyngitis, accounting for 15-30% of cases in children and 5-10% in adults (Alós et al. 2003). *S. pyogenes* is one of the most common human pathogens and causes both invasive and noninvasive infections. Invasive *S. pyogenes* infections include bacteremia, pneumonia, puerperal sepsis, cellulitis, necrotizing fasciitis, and streptococcal toxic shock syndrome. Noninvasive infections, predominantly tonsillitis and impetigo, account for a significant number of general practice consultations (Ekelund et al. 2005).

S. pyogenes has also been fairly consistently the fourth-most predominant pathogen causing pediatric acute otitis media (AOM), after *S. pneumoniae*, *Haemophilus influenzae*, and *Moraxella catarrhalis* (Shulman and Tanz 2005). There have been reports of bacterial meningitis as a complication of otitis media or mastoiditis due to *S. pyogenes* (Cohen-Kerem and Lavon 2002; Laupland and Bosch 2006). Generally, *S. pyogenes* forms non-mucoid colonies with a matt surface and causes *β*-hemolysis on sheep's blood agar medium (Chang et al. 2011; Wozniak et al. 2012). In Japan, mucoid *S. pyogenes* has rarely been reported because of the quite low detection rate of mucoid type isolates, and the epidemiological features of mucoid *S.*

Received February 5, 2014; revised and accepted March 26, 2014. Published online April 11, 2014; doi: 10.1620/tjem.232.301.
Correspondence: Risako Kakuta, M.D., Department of Otolaryngology, Head and Neck Surgery, Tohoku University Graduate School of Medicine, 1-1 Seiryomachi, Aoba-ku, Sendai 980-8574, Japan.
e-mail: kakuta-r@med.tohoku.ac.jp

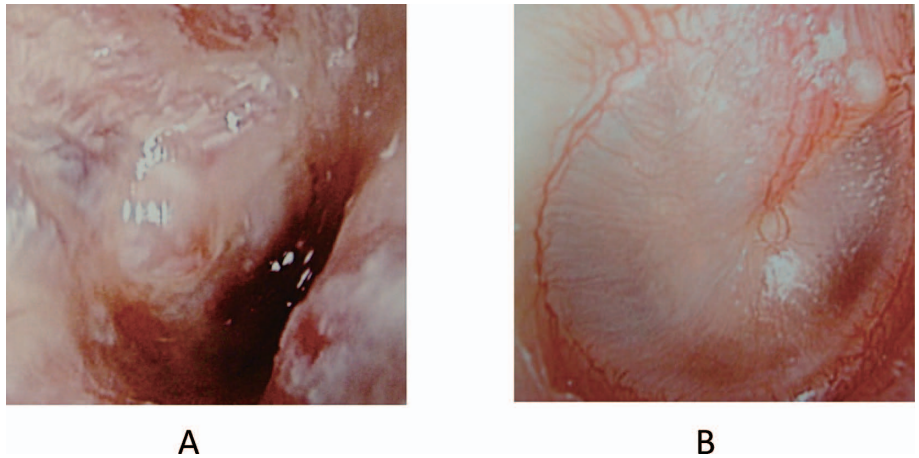

Fig. 1. Appearance of the tympanic membrane.
(A) At the time of admission: The circumferential wall of the right external auditory canal was bulging with little of the tympanic membrane being visible.
(B) Four months' after the treatment in our hospital: The right tympanic membrane became normal.

pyogenes infection are not fully understood. There has never been a report of mucoid β-hemolytic *S. pyogenes* causing AOM. Here, we report first case of severe AOM caused by mucoid *S. pyogenes* in a previously healthy adult.

Clinical Course and Isolate Characterization

In March 2012, a 36-year-old previously healthy woman presented to the Ear, Nose and Throat (ENT) clinic of another institution. She complained of a sore throat and right otalgia. AOM was diagnosed and right myringotomy was performed. Because of continuous serous discharge, she was referred to the ENT department of a general hospital. She had severe otalgia accompanied by headache, and was referred to the ENT department of Tohoku University Hospital with suspected cerebrospinal fluid otorrhea on the same day. The patient was fully conscious and there was no neck rigidity. Physical examination was unremarkable. Vital signs were normal, except that her temperature was 37.2°C. Otoscopy revealed pulsating serous discharge from the right ear and circumferential bulging of the wall of the right external auditory canal, with little of the tympanic membrane being visible (Fig. 1A). The left ear was normal. She complained of severe pain even if her ear was touched softly. She had no previous history of ear discharge or significant illness, but her daughter had developed pharyngitis a few days before. Pure tone audiometry demonstrated conductive hearing loss on the right side (pure tone average: 36.3 dB) and normal hearing on the left. Laboratory tests revealed a white blood cell count of 18,200/μL with 93% neutrophils and elevation C reactive protein to 7.0 mg/dL. Serum electrolytes, renal function tests, and liver function tests were normal. Computed tomography of the temporal bone demonstrated opacification of the right tympanic cavity and mastoid air cells without bony destruction. A qualitative sugar test (Lifesticks®; Siemens Japan K.K., Tokyo, Japan) of middle ear secretions was negative.

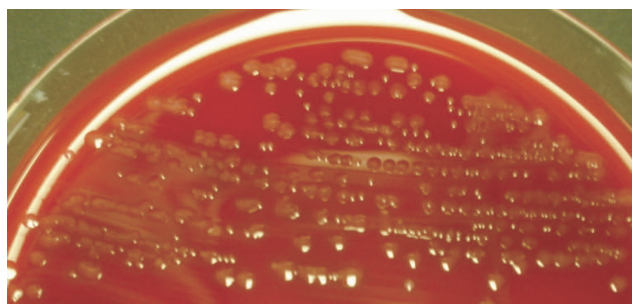

Fig. 2. Appearance of bacterial colonies.
Culture of middle ear secretions resulted in growth of mucoid colonies on blood agar plates. The colonies are surrounded by a zone of complete (beta) hemolysis.

Therefore, we thought it was more likely that she had severe AOM rather than cerebrospinal fluid otorrhea or meningitis. Sampling of middle ear secretions for bacterial culture was performed before treatment was started. A smear of the middle ear secretions showed Gram-positive cocci and chains. Antimicrobial therapy was commenced with intravenous meropenem (1.0 g/day). Culture of middle ear secretions on sheep blood agar plates (Nissui Pharmaceutical Co., Tokyo, Japan) grew mucoid colonies surrounded by a zone of complete β-hemolysis (Fig. 2). The antigen-agglutination test was negative for *Streptococcus pneumoniae* (Slidex pneumo-Kit®; Sysmex-bioMérieux Japan, Tokyo, Japan), but was positive for *S. pyogenes* (Seroiden Strepto Kit Eiken®; Eiken Chemical Co., Tokyo, Japan). Accordingly, it was considered that mucoid *S. pyogenes* could be the causative pathogen, so the patient's antimicrobial therapy was subsequently changed to panipenem-betamipron (2.0 g/day). After receiving antimicrobial therapy for a total of 10 days, all symptoms resolved other than slight persistent discharge from the right ear. Although middle ear fluid was seen after closure of the

tympanic perforation, the right ear was normal (Fig. 1B) and the patient was asymptomatic (pure tone average: 13.8 dB) at her 4-month follow-up examination.

We confirmed infection due to *S. pyogenes* by 16S ribosomal RNA gene sequencing (Baker et al. 2003; Johansson et al. 2004; Woo et al. 2008). Antimicrobial susceptibility testing was performed for 11 antibiotics by the broth microdilution method as recommended by the Clinical and Laboratory Standards Institute (2009). The minimum inhibitory concentrations (MICs) of the antimicrobial agents were as follows: ≤ 0.016 μg/mL for penicillin G, ≤ 0.06 μg/mL for ampicillin, ≤ 0.12 μg/mL for amoxicillin/clavulanic acid, ≤ 0.06 μg/mL for amoxicillin/sulbactam, ≤ 0.03 μg/mL for ceftriaxone, ≤ 0.016 μg/mL for cefditoren, > 8 μg/mL for erythromycin, ≤ 0.12 μg/mL for clindamycin, ≤ 0.008 μg/mL for panipenem, ≤ 0.008 μg/mL for meropenem, and 1 μg/mL for levofloxacin. Polymerase chain reaction (PCR) analysis was done for detection of the *erm*A, *erm*B, and *mef*A genes mediating macrolide resistance, as described previously (Sutcliffe et al. 1996; Seppala et al. 1998), revealing *mef*A in the isolated strain. PCR for *emm* genotyping was carried out according to the method described previously (Beall et al. 1996; Arai et al. 2011), and the M-protein genotype was determined to be *emm*75 by comparison with the Centers for Disease Control and Prevention (CDC) *emm* database (http://www.cdc.gov/ncidod/biotech/strept/strepblast.htm). Multilocus sequence typing (MLST) analysis (Enright et al. 2001) revealed that this isolate belonged to ST49 by comparison with the MLST database (http://spyogenes.mlst.net/).

Discussion

In Japan, mucoid *S. pyogenes* has rarely been reported and there has never been a report of mucoid β-hemolytic *S. pyogenes* causing AOM. However, mucoid *S. pyogenes* has occasionally been reported to cause invasive disease in other countries (Tamayo et al. 2010; Wozniak et al. 2012). The mucoid phenotype is due to abundant production of the hyaluronic acid capsular polysaccharide, a key virulence factor associated with severe *S. pyogenes* infection (Gryllos et al. 2008). Tamayo et al. (2010) described the clinical and molecular characteristics of mucoid strains causing outbreaks of infection, and compared them with non-mucoid *S. pyogenes* isolated during the same period. They found that invasive disease was more often due to mucoid isolates than non-mucoid isolates at their hospital (3% vs. 0.21%, P = 0.001). In our patient, it is considered that severe AOM occurred because of infection with mucoid *S. pyogenes*.

The M protein encoded by the *emm* gene is a major virulence factor of *S. pyogenes* and marked variability of *emm* gene sequences among *S. pyogenes* strains is an important surveillance tool, with more than 200 *emm* types currently listed in the online CDC database (http://www.cdc.gov/ncidod/biotech/strep/strepindex.htm). In the present patient with severe AOM, *S. pyogenes* was isolated from middle ear secretions, which had a mucoid shape and was characterized as *emm*75. According to the CDC (http://www.cdc.gov/ncidod/biotech/strep/emmtype_proportions.htm), *emm*75 is the eighth most frequently isolated *emm* type causing disease in Asian countries, being the third most frequent *emm* type isolated in patients with pharyngeal disease and less common in invasive disease. Thus, *S. pyogenes* possessing *emm*75 is commonly noninvasive, but our case suggests that severe symptoms may be caused by its mucoid form.

Macrolide resistance has gradually increased in *S. pyogenes* isolates around the world, including Japan (Wajima et al. 2008; Arai et al. 2011). Resistance of *S. pyogenes* to macrolides is mainly caused by two mechanisms: one involving 23S ribosomal RNA methylase genes (*erm*B and *erm*A) and the other involving the efflux determinant *mef*A (Sutcliffe et al. 1996; Seppala et al. 1998). In Japan, macrolide-resistant strains have been reported to account for 16.2% of *S. pyogenes* isolates, with the resistance genes *erm*A, *erm*B, and *mef*A being found in 2.5%, 6.2%, and 7.5% of strains, respectively (Wajima et al. 2008). Hotomi et al. evaluated 272 strains of *S. pyogenes* isolated in Japan, and they found that strains belonging to the *emm*75 or *emm*12 types harbored macrolide resistance genes significantly more frequently than other *emm* types and that *emm*75 strains also had *mef*A (Hotomi et al. 2009). Ardanuy et al. performed molecular characterization of *S. pyogenes* isolates in Barcelona, and reported that *emm*75-ST49 (the same *emm* and ST types as the isolate in our patient) was one of the most frequent genotypes that possessed *mef*A (Ardanuy et al. 2010). To date, *S. pyogenes* remains universally susceptible to penicillin, which comprises the treatment of choice in non-allergic patients so we could have treated her with penicillin.

In conclusion, mucoid *S. pyogenes* can cause severe infection even in previously healthy persons. Emergence of mucoid *S. pyogenes* and drug resistance trends should be monitored in the future.

Conflict of Interest

The authors declare no conflict of interest.

References

Alós, J.I., Aracil, B., Oteo, J. & Gómez-Garcés, J.L. (2003) Significant increase in the prevalence of erythromycin-resistant, clindamycin- and miocamycin-susceptible (M phenotype) *Streptococcus pyogenes* in Spain. *J. Antimicrob. Chemother.*, **51**, 333-337.

Arai, K., Hirakata, Y., Yano, H., Kanamori, H., Endo, S., Hirotani, A., Abe, Y., Nagasawa, M., Kitagawa, M., Aoyagi, T., Hatta, M., Yamada, M., Nishimaki, K., Takayama, Y., Yamamoto, N., et al. (2011) Emergence of fluoroquinolone-resistant *Streptococcus pyogenes* in Japan by a point mutation leading to a new amino acid substitution. *J. Antimicrob. Chemother.*, **66**, 494-498.

Ardanuy, C., Domenech, A., Rolo, D., Calatayud, L., Tubau, F., Ayats, J., Martín, R. & Liñares, J. (2010) Molecular characterization of macrolide- and multidrug-resistant *Streptococcus pyogenes* isolated from adult patients in Barcelona, Spain (1993-2008). *J. Antimicrob. Chemother.*, **65**, 634-643.

Baker, G.C., Smith, J.J. & Cowan, D.A. (2003) Review and re-analysis of domain-specific 16S primers. *J. Microbiol. Methods*, **55**, 541-555.

Beall, B., Facklam, R. & Thompson, T. (1996) Sequencing *emm*-specific PCR products for routine and accurate typing of group A streptococci. *J. Clin. Microbiol.*, **34**, 953-958.

Chang, H., Shen, X., Huang, G., Fu, Z., Zheng, Y., Wang, L., Li, C., Liu, L., Shen, Y., Liu, X. & Yang, Y. (2011) Molecular analysis of *Streptococcus pyogenes* strains isolated from Chinese children with pharyngitis. *Diagn. Microbiol. Infect. Dis.*, **69**, 117-122.

Clinical and Laboratory Standards Institute (2009) *Performance standards for antimicrobial susceptibility testing; 19th informational supplement*, M100-S19, Clinical and Laboratory Standards Institute, Wayne, PA.

Cohen-Kerem, R. & Lavon, H. (2002) Group-A streptococcal meningitis in an adult, secondary to purulent otitis media. *J. Laryngol. Otol.*, **116**, 541-542.

Ekelund, K., Darenberg, J., Norrby-Teglund, A., Hoffmann, S., Bang, D., Skinhøj, P. & Konradsen, H.B. (2005) Variations in *emm* type among group A streptococcal isolates causing invasive or noninvasive infections in a nationwide study. *J. Clin. Microbiol.*, **43**, 3101-3109.

Enright, M.C., Spratt, B.G., Kalia, A., Cross, J.H. & Bessen, D.E. (2001) Multilocus sequence typing of *Streptococcus pyogenes* and the relationships between *emm* type and clone. *Infect. Immun.*, **69**, 2416-2427.

Gryllos, I., Tran-Winkler, H.J., Cheng, M.F., Chung, H., Bolcome, R. 3rd., Lu, W., Lehrer, R.I. & Wessels, M.R. (2008) Induction of group A Streptococcus virulence by a human antimicrobial peptide. *Proc. Natl. Acad. Sci. USA*, **105**, 16755-16760.

Hotomi, M., Billal, D.S., Togawa, A., Ikeda, Y., Takei, S., Kono, M., Ogami, M., Ubukata, K., Sugita, R., Fujihara, K. & Yamanaka, N. (2009) Distribution of fibronectin-binding protein genes (prtF1 and prtF2) and streptococcal pyrogenic exotoxin genes (spe) among *Streptococcus pyogenes* in Japan. *J. Infect. Chemother.*, **15**, 367-373.

Johansson, K.E., Duhamel, G.E., Bergsjö, B., Engvall, E.O., Persson, M., Pettersson, B. & Fellström, C. (2004) Identification of three clusters of canine intestinal spirochaetes by biochemical and 16S rDNA sequence analysis. *J. Med. Microbiol.*, **53**, 345-350.

Laupland, K.B. & Bosch, J.D. (2006) Acute group A streptococcal mastoiditis complicated by pneumocephaly in a previously healthy adult. *Scand. J. Infect. Dis.*, **38**, 719-721.

Seppala, H., Skurnik, M., Soini, H., Roberts, M.C. & Huovinen, P. (1998) A novel erythromycin resistance methylase gene (*ermTR*) in *Streotococcus pyogenes*. *Antimicrob. Agents Chemother.*, **42**, 257-262.

Shulman, S.T. & Tanz, R.R. (2005) Streptococcal otitis media: from epidemiology to pathogenesis. *Clin. Infect. Dis.*, **41**, 42-44.

Sutcliffe, J., Grebe, T., Tait-Kamradt, A. & Wondrack, L. (1996) Detection of erythromycin-resistant determinants by PCR. *Antimicrob. Agents Chemother.*, **40**, 2562-2566.

Tamayo, E., Montes, M., García-Medina, G., García-Arenzana, J.M. & Pérez-Trallero, E. (2010) Spread of a highly mucoid *Streptococcus pyogenes emm*3/ST15 clone. *BMC Infect. Dis.*, **10**, 233.

Wajima, T., Murayama, S.Y., Sunaoshi, K., Nakayama, E., Sunakawa, K. & Ubukata, K. (2008) Distribution of *emm* type and antibiotic susceptibility of group A streptococci causing invasive and noninvasive disease. *J. Med. Microbiol.*, **57**, 1383-1388.

Woo, P.C., Lau, S.K., Teng, J.L., Tse, H. & Yuen, K.Y. (2008) Then and now: use of 16S rDNA gene sequencing for bacterial identification and discovery of novel bacteria in clinical microbiology laboratories. *Clin. Microbiol. Infect.*, **14**, 908-934.

Wozniak, A., Rojas, P., Rodríguez, C., Undabarrena, A., Garate, C., Riedel, I., Román, J.C., Kalergis, A.M. & García, P. (2012) M-protein gene-type distribution and hyaluronic acid capsule in group A Streptococcus clinical isolates in Chile: association of *emm* gene markers with csrR alleles. *Epidemiol. Infect.*, **140**, 1286-1295.