

Functional Analysis after Auto Iris Pigment Epithelial Cell Transplantation in Patients with Age-Related Macular Degeneration

TOSHIAKI ABE, MADOKA YOSHIDA, HIROSHI TOMITA,
TETSUYA KANO, YOICHI NAKAGAWA, MASAMI SATO,
YUKO WADA, NOBUO FUSE, TASUKU YAMADA and
MAKOTO TAMAI

*Department of Ophthalmology, Tohoku University, School
of Medicine, Sendai 980-8574*

ABE, T., YOSHIDA, M., TOMITA, H., KANO, T., NAKAGAWA, Y., SATO, M., WADA, Y., FUSE, N., YAMADA, T. and TAMAI, M. *Functional Analysis after Auto Iris Pigment Epithelial Cell Transplantation in Patients with Age-Related Macular Degeneration.* Tohoku J. Exp. Med., 1999, **189** (4), 295-305 — Recent transplantation studies indicate that subretinal space is not always an immunologically privileged site and non-autologous cells may be rejected in patients with exudative age-related macular degeneration (AMD). We performed autologous iris pigment epithelial (IPE) cell transplantation by cell suspension after autologous IPE cell culture in 8 patients with AMD. These patients were followed without immunosuppression between 1.5 and 8 months and the retinal function was analyzed. No cystoid macular edema or fluorescein leakage was observed. Six of the 8 patients improved visual acuity of more than two lines and the other two patients retained preoperative visual acuity. Five patients had increased visual field sensitivity, one patient retained pretransplantation sensitivity, and one patient showed a gradual decrease in sensitivity (one patient was not examined). Although 2 of the 8 patients showed decreased amplitude of flicker electroretinography (ERG) (about 60 to 70% as that of preoperative level), the average improvement of each amplitude of a single white flash (a wave), photopic, or flicker ERG was 123, 102, and 107%, respectively. No proliferative change in the submacular lesion or vitreous cavity was observed after transplantation. From this functional analysis, transplanted autologous IPE may have, in part, an alternative function in regard to the retinal pigment epithelium in the subretinal space. ——— auto iris pigment epithelium; rejection; transplantation © 1999 Tohoku University Medical Press

Transplantation of neural retina (Jiang et al. 1993), retinal pigment epithelium (RPE) (Li and Turner 1991; Sheedlo et al. 1991; Lavail et al. 1992; Zhang and Bok 1998) and iris pigment epithelium (IPE) (Tamai et al. 1997; Rezai et al.

Received November 14, 1999; revision accepted for publication December 15, 1999.

Address for reprints: Toshiaki Abe, Department of Ophthalmology, Tohoku University School of Medicine, 1-1 Seiryomachi, Aoba-ku, Sendai 980-8574, Japan.

e-mail: toshi@oph.med.tohoku.ac.jp

1997a; Thumann et al. 1997) have been performed in the subretinal place using animal models such as Royal College of Surgeons (RCS) rats, whose original condition contributed to the dysfunction of the phagocytosis of the RPE (Bok and Hall 1971). The results of the transplantation have shown partial preservation of photoreceptor cells. Recently, the transplantation of fetal RPE cells has also been evaluated in human age-related macular degeneration (AMD) (Algvere et al. 1997).

Some of the findings revealed a thickening of the macula, fluorescein leakage, and a gradual decrease of visual acuity; these may have been due to graft rejection. The patients who showed host-graft rejection in the study had neovascular membranes and destruction of the blood-retinal barrier. Peyman et al. (1991) also reported that autologous transplantation in exudative AMD improved visual acuity, but homologous transplantation did not. The patient with homologous transplantation also showed encapsulation of the transplanted tissue. As reported by Zhang and Bok (1998), systemic immunity may also exert a significant influence on the transplanted cells in the subretinal space with the breakdown of the blood-retinal barrier. These results indicate that subretinal space is not always an immunologically privileged site (Nieder Korn and Streilein 1986; Streilein 1990) and non-autologous cells may be rejected in AMD patients with neovascularization.

IPE has the same embryonic origin as RPE and may perform an alternative function similar to that of RPE (Rezai et al. 1997a, b, c; Abe et al. 1999a). However, recent reports also show that transplanted fresh allogeneous IPE significantly rescued photoreceptors when compared to untransplanted eyes. In the short term, the transplants were not as remarkable as RPE transplants (Schraermeyer et al. 1999). To supply an alternative function of the defected RPE and to minimize host-graft rejection, we performed autologous IPE cell transplantation (Abe et al. 1999a). To date no study has precisely evaluated the retinal function after transplantation. To evaluate autologous IPE transplantation from the point of retinal function, we examined the macular function after autologous IPE cell transplantation in exudative AMD patients.

SUBJECTS AND METHODS

Patients

Eight patients with AMD (2 females and 6 males) participated in the study (Table 1). All patients showed unilateral lesion of AMD. Fellow eyes worse than 0.9 were considered either cataract or amblyopia from the examination. The patients ranged from 49 to 85 years of age (average 69.6 years old). The duration between the initial eye symptoms and transplantation ranged 3 to 17 months (average 10.2 months). Preoperative visual acuity were between hand motion (HM) and 0.05 in the patients. All of these patients showed neovascular membranes either by fluorescein angiography (FAG) and/or indocyanine green angio-

TABLE 1. *Visual acuity and percentage improvement of each amplitude of a and b waves of a single white flash ERG, photopic ERG, or flicker ERG of pretransplantation and posttransplantation*

Age/ Gendar	Visual acuties pre/post	Cells (culture days)	ERG a wave	ERG b wave	ERG photopic	ERG flicker
			% recovery (pre/post % amplitude)			
1. 66/M	0.02/0.04	5 × 10 ⁴ (39)	97.6 (103/100)	89.1 (103/92)	100 (100/100)	103.0 (61/63)
2. 49/F	0.05/0.1	10 × 10 ⁴ (40)	112.1 (87/97)	105.7 (90/95)	106.8 (88/94)	117.5 (80/94)
3. 58/F	CF/0.04	2 × 10 ⁴ (27)	144.5 (69/100)	131.2 (80/105)	92.0 (100/92)	90.0 (100/90)
4. 85/M	0.01/0.1	21 × 10 ⁴ (35)	94.0 (100/94)	103.1 (97/100)	97.0 (85/83)	86.0 (100/86)
5. 70/M	0.02/0.04	10 × 10 ⁴ (30)	235.6 (17/41)	237.0 (13.5/32)	125.5 (32/40)	235.3 (17/40)
6. 73/M	0.04/0.1	3 × 10 ⁴ (40)	111.3 (97/108)	110.0 (100/110)	118.9 (79/94)	97.2 (71/69)
7. 79/M	HM/HM	1 × 10 ⁴ (60)	87.8 (33/29)	110.0 (30/33)	83.0 (47/39)	60.5 (33/20)
8. 77/M	0.04/0.04	5 × 10 ⁴ (35)	102 (125/128)	110.3 (107/118)	90.5 (117/106)	68.1 (87/59)
Average(%)			123.1	123.3	101.7	107.2

CF indicates counting finger and HM identifies hand motion. Cells indicate the number of transplanted cells.

graphy (ICG). The sizes of the neovascular membranes were estimated to be between 0 and 3 disc diameter (DD) by FAG and 0.2 and 2 DD by ICG. Follow up periods were between 1.5 and 8 months.

One patient (Case 7 in Table 1) was treated by radiation (20 Gy) for neovascularization (Chakravarthy et al. 1998; Finger et al. 1998). Six months before the transplantation. These transplanted patients were followed without immunosuppression. For control, the visual acuity of 48 patients with AMD who had undergone only removal of the neovascular membranes were evaluated. Unfortunately, not all of these patients received other clinical evaluations and we compared only the visual acuity among these patients. The methods of operation are described below and nothing differed among these patients except for cell transplantation.

Human research

The tenets of the Declaration of Helsinki were followed, and informed consent was obtained from all subjects who participated in this study after an explanation of the nature and possible consequences of the experiment. This study was also approved by the ethics committee of Tohoku University, Sendai on

January 26, 1998.

Clinical evaluations

Patients who underwent autologous IPE cell transplantation were examined ophthalmologically at Tohoku University Hospital. The subsequent ophthalmic examinations included best corrected visual acuity, slit lamp biomicroscopy, visual field analysis, fundus examination and photography, FAG and ICG by scanning laser ophthalmoscopy (SLO) (Rodestock, Munich, Germany), optic coherence tomography (OCT) (Humphrey system, Carl Zeiss, Dublin, CA, USA), and electroretinographies. The best corrected visual acuity included the grading of very low visual acuity (Case 7) using a Low Vision Evaluator (LoVE) (Mayo, Nagoya) (Tamai et al. 1999). To describe this experiment briefly, the patient covers one eye with a goggle and wears a set of earphones to hear a click before light stimulation. A light emission diode (LED) emits light at three levels: 10 cd/mm²(C), 100 C, 1000 C, and their duration in 0.1 second (sec), 0.3 sec, 1 sec, respectively. Therefore, the patients receive 9 different levels of stimulus intensity, 5 times each for a total of 45 times per eye. False positive response was also recorded and the reliability of the data was assessed. Microperimetry of the macular area was also performed by SLO. When possible, a visual field analysis was performed with a Humphrey visual field analyzer with program 30-2 (Carl Zeiss). The electroretinogram (ERG) was obtained using a bright white flash with the subject in a dark-adapted state and a single flash or a 30-Hz flicker stimulus of red light under light-adapted conditions for cone-isolated responses under controlled conditions that confirm to the standard of the International Standardization Committee (Marmor 1995). Because all patients in this study had affected unilateral eyes and the amplitude of each a and b wave of a single flash ERG, photopic ERG, and flicker ERG was compared to the unaffected eyes and were shown by % amplitude. Pretransplantation and posttransplantation examinations were performed.

IPE cell preparation

IPE cell cultures were performed by the modification methods as previously reported for RPE (Abe et al. 1998). In brief, the iris was incubated with 0.25% trypsin in Dulbecco's (Gibco BRL, Bethesda, MD, USA) solution at 37°C for 20 minutes after peripheral iridectomy prior to transplantation. After incubation, the IPE was mechanically detached from the stroma, and pipetting was performed. Then the IPE cells were seeded at 37°C in 5% CO₂ in 15% autologous serum in F-12 medium (Gibco). The autologous serum was collected by a venous puncture (Abe et al. 1999b). The medium was changed every three day. A suspension of cultured IPE cells were obtained using a trypsin-ethylenediaminetetraacetic acid (EDTA) solution (0.125% trypsin and 0.2 mM EDTA), and the cells were collected by centrifugation after stopping the reaction.

The cells were washed with balanced salt solution (BSS) 3 times and suspended in 15–20 μ l of a BSS 30 minutes before the transplantation. The number of cells injected into the subretinal space was approximately $2\sim 21 \times 10^4$ (average 7×10^4) cells. The duration of the culture was between 27 and 60 days (average 30.8 days). All these procedures were performed in the special “semi-sterile room” at the Department of Ophthalmology, Tohoku University.

Surgical procedures

The surgical procedures were the same as those of our previously reported method (Abe et al. 1999a). Briefly, 8 neovascular membranes from 8 patients with AMD were removed through intentional microretinal holes of the retina during a 3-port vitrectomy. A tiny retinal bleb was made by injecting BSS through a small bented needle before extracting the neovascular membranes. The neovascular membranes were removed from microretinal holes. After removing the neovascular membranes, the subretinal space was washed by a specially designed microinjection needle (Abe et al. 1999a). The needle was made with two parts in one shaft, which could be controlled separately; one for cell injection and the other for BSS injection or aspiration. Under microscopic control, the needle was inserted into the subretinal space by the surgeon after a fluid-air exchange. The assistant controlled the subretinal space by injecting BSS into the subretinal space using one of the ports and injecting the cultured IPE cells using the other port under microscopic control. All of the procedures described above were performed through microretinal holes and the injection was performed by cell suspension. Four of the eight patients also received a lensectomy with an intraocular lens (IOL) implantation. After the procedure, the vitreous cavity was exchanged by 20% of sulfur hexafluoride (SF_6). The patients lay on their backs for four hours and were positioned face down overnight.

Statistical analysis

Statistical significance was determined by using the chi-square test, Mann-Whitney's test, or Student's *t*-test. A *p* value less than 0.05 was considered significant.

RESULTS

Autologous IPE cell culture was established successfully from all of the patients. Cytokeratin immunocytochemistry confirmed that these cells were epithelial in origin (data not shown). The cell number used for transplantation and duration required for cell culture was not proportional. One patient (Case 7) showed slow cell growth (60 days for 2×10^4 cells), when compared to those of other patients (less than 40 days for at least 3×10^4 cells).

All patients showed active neovascular membranes, which were confirmed either by FAG and/or ICG with a variable amount of submacular hemorrhages,

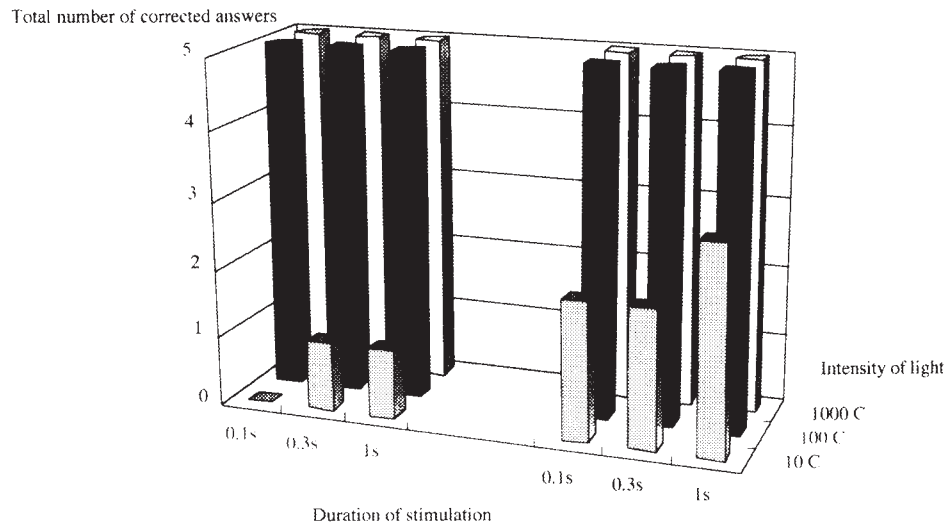


Fig. 1. The result of LoVE is shown (Case 7).

The transplanted eye was stimulated by LED in three levels: 10 C (▣), 100 C (■), 1000 C (□), at a duration of 0.1 second (sec), 0.3 sec, and 1 sec, respectively. So the patient was stimulated with 9 different levels of stimulus intensity, 5 times each for a total of 45 trials. Left and right panels show the results of pretransplantation and posttransplantation, respectively.

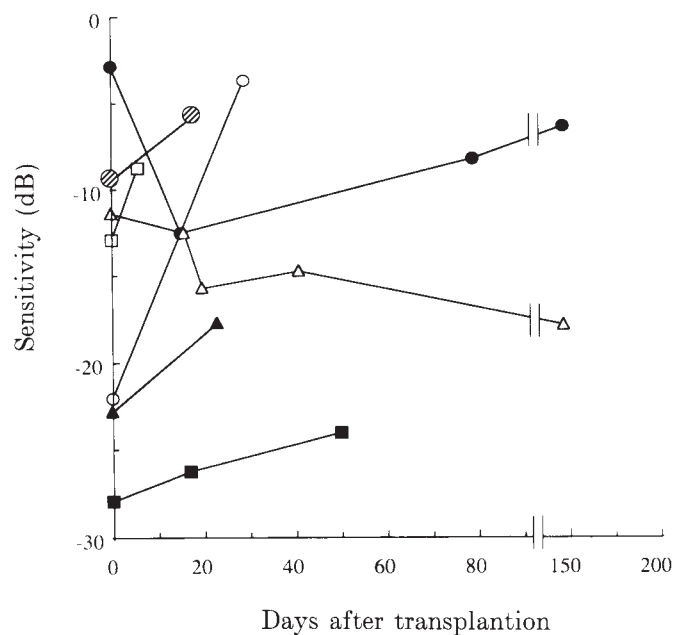


Fig. 2. The sensitivity of Humphrey visual field analysis (program 30-2) were measured for pretransplantation and posttransplantation. ○, Patient 1; ●, Patient 2; △, Patient 3; ▲, Patient 5; ◻, Patient 6; ■, Patient 7; ⊗, Patient 8.

exudates, fibrovascular membranes, and serous retinal detachments. Autologous IPE cell suspensions were transplanted into the subretinal space after the removal of the neovascular membranes in 8 patients with AMD. The clinical characteristics and fundus figures have already been reported (Abe et al. 1999a). These patients were followed without immunosuppression. A varying degree of atrophies or defects of choriocapillaris and RPE was observed. One patient (Case 3)

developed mild preretinal fibrosis and another patient (Case 1) showed submacular fibrosis. A faint hyperfluorescence (window defect) on FAG, probably due to the injury of RPE or a defect of RPE, was observed in these patients. No abnormal indocyanine green leakage was observed by ICG at the transplanted area. Also no distinct transplanted cells were visible by direct ophthalmoscopy, SLO or OCT. The results of microperimetry varied among the patients.

Visual acuity of pretransplantation and posttransplantation (most recent) are shown in Table 1. Six of the eight patients showed improved visual acuity and the other two patients retained preoperative visual acuity. Conversely, approximately 25% of the control patients with AMD, who were treated only by the removal of the neovascular membranes, showed a decrease in visual acuity (data not shown), although the statistical analysis was not significant ($p=0.082$). One of the patients (Case 7) showed very low visual acuity (HM) and evaluated by LoVE. The results are shown in Fig. 1. The best corrected visual acuity of the 79-year-old man was HM before transplantation. However, he could respond to the light stimulation with 1000 C and 100 C in any duration but partly failed with 10 C (left panel in Fig. 1). After transplantation, his visual acuity was still HM, but the response to light stimulation was better than that before transplantation (right panel in Fig. 1).

The threshold of Humphrey visual field analysis of preoperative and postoperative follow up examinations is also shown in Fig. 2. One patient (Case 3) gradually deteriorated the mean sensitivity during successive follow ups. Another patient (Case 2) showed a temporally deteriorated mean sensitivity, but recovered gradually, almost to the preoperative level. All other patients showed increased sensitivity after transplantation. One patient was not given the preoperative visual field analysis, therefore the result is not shown (Case 7).

The results of the electrophysiological analysis are shown in Table 1. As described previously, all patients in this study had affected unilateral eyes. The amplitude of each a and b wave of a single flash ERG, photopic ERG, and flicker ERG was compared to the unaffected eyes and were shown by % of amplitude. The % recovery of each amplitude of posttransplantation against pretransplantation are shown in the Table. The average % recovery ratio of a and b waves of a single flash ERG, photopic ERG, and flicker ERG showed 123%, 123%, 102%, and 107%, respectively. Lower amplitudes directly reflect larger exudative changes of the subretinal lesions among patients (data not shown). More than half of the patients improved or maintained pretransplantation amplitudes. However, the amplitude of flicker ERG in some patients (Cases 7 and 8) was about 60 to 70% compared to that of pretransplantation.

DISCUSSION

Transplantation other than autologous cells may generate rejection in patients with exudative AMD, even though the subretinal space has reportedly

been an immunologically privileged site (Nieder Korn and Streilein 1986; Streilein 1990). Consequent use of immunosuppression for preventing host-graft rejection may cause infection and toxicity (Wongpichedchai et al. 1992). Although autologous RPE transplantation from the peripheral retina to the posterior pole was reported in rabbit model (Wongpichedchai et al. 1992) or human cadaver eyes (Ishida et al. 1998), it may be difficult to apply in humans because of the complicated isolation techniques and the low viability of isolated cells (Rezai et al. 1997a). To minimize these problems, we performed autologous IPE cell transplantation in patients with AMD (Abe et al. 1999a). No patients in our study showed cystoid macular edema, gradually decreased visual acuity, and fluorescein or indocyanine green leakage after transplantation, which may be an early indicator of host-graft rejection (Sheng et al. 1995; Algvere et al. 1997). These results indicate no apparent host-graft rejection at the transplanted lesion in our patients. Because transplanted cells were in the form of cell suspension and less pigmented than that of the original IPE, these cells were not visible in our patients during successive follow up examinations even though we used SLO or OCT. Algvere and coworkers (Algvere et al. 1997) also reported that transplanted RPE cells by cell suspension were not visible, although they transplanted the cells in patients with nonexudative AMD. Therefore, functional analysis of the retina at the transplanted lesion may be necessary for follow up evaluations of the patients. By examination of not only visual acuity but visual field analysis and ERGs, we analyzed the retinal functions after transplantation.

IPE cells grew well with autologous serum, although the proliferation rate of each cell was different among the patients. Case 7 showed slow cell growth in spite of the same procedure of the IPE isolation and culture methods. As described above, this patient had a history of exposure to 20 Gy radiation for neovascularization (Chakravarthy et al. 1998; Finger et al. 1998). The slow cell growth may be due to radiation. As auto antibodies against retina have been suspected to be elevated in patients with AMD (Penfold et al. 1990; Gurne et al. 1991), auto antibodies against IPE may also be present in some of these patients. Comparison of the cell growth against normal serum are ongoing in our department.

Visual acuity improved in 6 of the 8 patients. Although the other two patients maintained preoperative visual acuity, one of the patients with low vision (HM) showed a better reaction to the LED of LoVE after transplantation. As discussed by Tamai and coworkers (Tamai et al. 1999), this device may have the potential to evaluate the effect of transplantation in patients with very low vision; patients who could not be evaluated by other methods such as visual field analysis, ERGs or standard visual evaluation.

The sensitivity of the Humphrey visual field analysis showed that although only one patient (Case 3) gradually decreased in sensitivity, almost all other patients retained mean sensitivity more than in the preoperative condition. The

Case 3 patient developed mild preretinal fibrosis and we speculate that preretinal fibrosis may have influenced the result of his visual field analysis. So far we do not know the relationship between preretinal fibrosis and transplantation, about 31% of patients who underwent only removal of subretinal neovascularization in our clinic showed either sub or preretinal fibrosis ($p=0.517$) (unpublished data). We believe that the preretinal fibrosis in the patient may not relate to the procedure of transplantation, but relate to the surgical procedure or wound healing reaction of the lesion.

We found that the average amplitude from these patients improved after transplantation. However, we also found that not all patients showed improvement of each amplitude, especially the amplitude of flicker ERG in some patients (Cases 7 and 8). The discrepancy between the visual acuity or sensitivity of visual field and the electrophysiological results of some of the patients may be explained as follows. From our animal experiments, the transplanted cells at the subretinal space were located only in limited places but not covered the area of the microretinal detachment (unpublished data). Therefore, the results of the total reaction of the relatively large field, even though the examination was a 30-Hz flicker ERG, may be influenced by not only cell transplanted lesion but by the large untransplanted area. As shown by other authors (Sheng et al. 1995; Algvere et al. 1997), making microbleb at subretinal space generates mild injury to RPE and shows a window defect on FAG. Our cases also showed a mild window defect on FAG probably due to the injury or the defect of RPE. These results may also show that transplanted cells do not cover all of the lesions and may affect the electrophysiological results. Because these results were also from relatively early days of posttransplantation, it may take time to gain or improve the function. The results of visual acuity and visual field analysis may also be influenced psychophysiologically, careful follow-up examinations will be necessary.

Acknowledgments

This work was supported in part by grants from the Japanese Retinitis Pigmentosa Society and Grant-in-Aid for Scientific Research (C) (No. 10671630) (Dr. Abe) from the Ministry of Education, Science, Sports and Culture, Japan and the Research Committee on Choriorretinal Degeneration, the Ministry of Health and Welfare (Dr. Tamai), Japan.

References

- 1) Abe, T., Sato, M. & Tamai, M. (1998) Dedifferentiation of the retinal pigment epithelium compared to the proliferative membranes of proliferative vitreoretinopathy. *Curr. Eye Res.*, **17**, 1103–1109.
- 2) Abe, T., Tomita, H., Yoshida, M., Kano, T., Ohashi, T., Sato, M. & Tamai, M. (1999a) Iris pigment epithelial cell transplantation in patients with age-related macular degeneration. *Invest. Ophthalmol. Vis. Sci.*, **40**, S724. (Abstracts)
- 3) Abe, T., Tomita, H., Ohashi, T., Yamada, K., Takeda, Y., Akaishi, K., Yoshida, M., Sato, M. & Tamai, M. (1999b) Characterization of iris pigment epithelial cell for

- auto cell transplantation. *Cell Transplant.*, **8**, 501-510.
- 4) Algvere, P.V., Berglin, L., Gouras, P., Sheng, Y. & Kopp, E.D. (1997) Transplantation of RPE in age-related macular degeneration: Observations in disciform lesions and dry RPE atrophy. *Graefes Arch. Clin. Exp. Ophthalmol.*, **235**, 149-158.
 - 5) Bok, D. & Hall, M.O. (1971) The role of the pigment epithelium in the etiology of inherited retinal dystrophy in the rat. *J. Cell Biol.*, **49**, 664-682.
 - 6) Chakravarthy, U., Hart, P. & Finger, P. (1998) External beam radiation therapy for CNV. *Ophthalmology*, **105**, 1790-1791.
 - 7) Finger, P.T., Chakravarthy, U. & Augsburger, J.J. (1998) Radiotherapy and the treatment of age-related macular degeneration. External beam radiation therapy is effective in the treatment of age-related macular degeneration. *Arch. Ophthalmol.*, **116**, 1507-1511.
 - 8) Gurne, D.H., Tso, M.O., Edward, D.P. & Ripps, H. (1991) Antiretinal antibodies in serum of patients with age-related macular degeneration. *Ophthalmology*, **98**, 602-607.
 - 9) Ishida, M., Lui, G.M., Yamani, A., Sugino, I.K. & Zarbin, M.A. (1998) Culture of human retinal pigment epithelial cells from peripheral scleral flap biopsies. *Curr. Eye Res.*, **17**, 392-402.
 - 10) Jiang, L.Q., Jorquera, M. & Streilein, J.W. (1993) Subretinal space and vitreous cavity as immunologically privileged sites for retinal allografts. *Invest. Ophthalmol. Vis. Sci.*, **34**, 3347-3354.
 - 11) Lavail, M.M., Li, L., Turner, J.E. & Yasumura, D. (1992) Retinal pigment epithelial cell transplantation in RCS rats: Normal metabolism in rescued photoreceptors. *Exp. Eye Res.*, **55**, 555-562.
 - 12) Li, L. & Turner, J.E. (1991) Optimal conditions for long-term photoreceptor cell rescue in RCS rats: The necessity for healthy RPE transplants. *Exp. Eye Res.*, **52**, 669-679.
 - 13) Marmor, M.F. (1995) An updated standard for clinical electroretinography. *Arch. Ophthalmol.*, **113**, 1375-1376.
 - 14) Niederkorn, J.Y. & Streilein, J.W. (1986) Lymphoma allografts abrogate immune privilege within the anterior chamber of the eye. *Invest. Ophthalmol. Vis. Sci.*, **27**, 1235-1243.
 - 15) Penfold, P.L., Provis, J.M., Furby, J.H., Gatenby, P.A. & Billson, F.A. (1990) Autoantibodies to retinal astrocytes associated with age-related macular degeneration. *Graefes Arch. Clin. Exp. Ophthalmol.*, **228**, 270-274.
 - 16) Peyman, G.A., Blinder, K.J., Paris, C.L., Alturki, W., Nelson, N.C., Jr. & Desai, U. (1991) A technique for retinal pigment epithelium transplantation for age-related macular degeneration secondary to extensive subfoveal scarring. *Ophthalmic Surgery*, **22**, 102-108.
 - 17) Rezai, K.A., Kohen, L., Wiedemann, P. & Heimann, K. (1997a) Iris pigment epithelium transplantation. *Graefes Arch. Clin. Exp. Ophthalmol.*, **235**, 558-562.
 - 18) Rezai, K.A., Lappas, A., Farrokh-Siar, L., Kohen, L., Wiedemann, P. & Heimann, K. (1997b) Iris pigment epithelial cells of long evans rats demonstrate phagocytic activity. *Exp. Eye Res.*, **65**, 23-29.
 - 19) Rezai, K.A., Lappas, A., Kohen, L., Wiedemann, P. & Heimann, K. (1997c) Comparison of tight junction permeability for albumin in iris pigment epithelium and retinal pigment epithelium in vitro. *Graefes Arch. Clin. Exp. Ophthalmol.*, **235**, 48-55.
 - 20) Schraermeyer, U., Kociok, N. & Heimann, K. (1999) Rescue effects of IPE transplants in RCS rats: Short-term results. *Invest. Ophthalmol. Vis. Sci.*, **40**, 1545-1556.
 - 21) Sheedlo, H.J., Li, L. & Turner, J.E. (1991) Photoreceptor cell rescue at early and late RPE-cell transplantation periods during retinal disease in RCS dystrophic rats. *J. Neural Transplant. Plast.*, **2**, 55-63.
 - 22) Sheng, Y., Gouras, P., Cao, H., Berglin, L., Kjeldbye, H., Lopez, R. & Roskoth, H.

- (1995) Patch transplants of human fetal retinal pigment epithelium in rabbit and monkey retina. *Invest. Ophthalmol. Vis. Sci.*, **36**, 381-390.
- 23) Streilein, J.W. (1990) Anterior chamber associated immune deviation: The privilege of immunity in the eye. *Surv. Ophthalmol.*, **35**, 67-73.
- 24) Tamai, M., Takeda, Y., Yamada, K., Akaishi, K., Tomita, H., Abe, T., Kojima, S. & Ishiguro S. (1997) bFGF transfected iris PE may rescue photoreceptor cell degeneration in RCS rat. In: *Retinal Degeneration*, edited by M.M. LaVail, R.E. Anderson & J.G. Hollyfield, Plenum Press, New York, London, pp. 323-328.
- 25) Tamai, M., Kunikata, H. & Tsunoda, M. (1999) Grading device for light perception with retinitis pigmentosa. In: *Retinal Degeneration*, edited by M.M. LaVail, R.E. Anderson & J.G. Hollyfield, Plenum Press, New York, London, pp. 215-222.
- 26) Thumann, G., Schraermeyer, U., Bartz-Schmidt, K.U. & Heimann, K. (1997) Descemet's membrane as membranous support in RPE/IPE transplantation. *Curr. Eye Res.*, **16**, 1236-1238.
- 27) Wongpichedchai, S., Weiter, J.J., Weber, P. & Dorey, C.K. (1992) Comparison of external and internal approaches for transplantation of autologous retinal pigment epithelium. *Invest. Ophthalmol. Vis. Sci.*, **33**, 3341-3352.
- 28) Zhang, X. & Bok, D. (1998) Transplantation of retinal pigment epithelial cells and immune response in the subretinal space. *Invest. Ophthalmol. Vis. Sci.*, **39**, 1021-1027.
-